

MODULE 7 L02

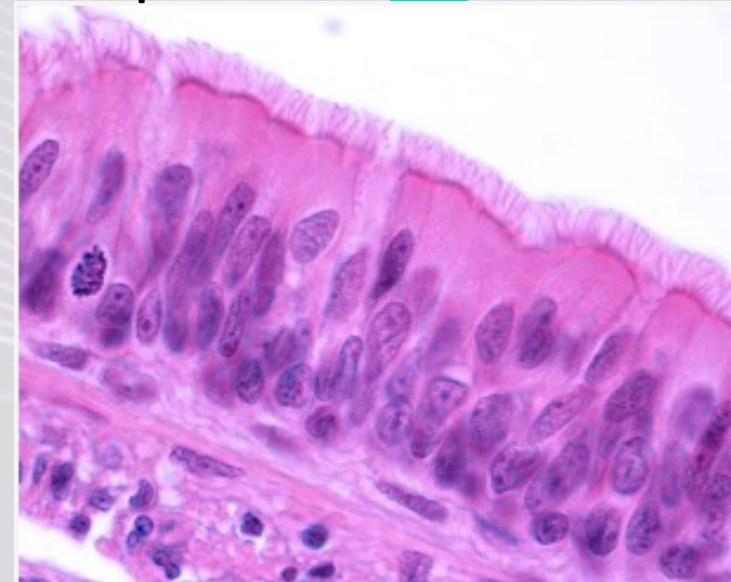
Functions of Respiratory Epithelia

Dr. Lisa Brinn
lbrinn@fiu.edu



2. Respiratory Epithelium

- Pseudostratified ciliated columnar epithelium
 - ❖ All of respiratory tract
 - Except:
 - Inferior portions of pharynx
 - Nonkeratinized stratified squamous epithelium
 - Alveoli
 - Simple squamous epithelium



Mucous Escalator

- Besides ciliated columnar epithelial cells
 - ❖ Basal progenitor cells
 - ❖ Club cells
 - ❖ Tuft cells
 - ❖ Ionocytes
 - ❖ Neuroendocrine cells
 - ❖ Goblet cells

